

Maxilla bone pre-surgical evaluation aided by 3D models obtained by Rapid Prototyping

Luís Queijo, João Rocha, Luísa Barreira & Tiago Barbosa

Instituto Politécnico de Bragança, Bragança, Portugal

André Ramos

Clínica Avenida – Medicina Dentária, Bragança, Portugal

Manuel San Juan

ESTII – Universidad de Valladolid; CIBER – Centro de Investigación Biomecánica y Ergonomía, Valladolid, Spain

ABSTRACT: For implant planning and placement, the association of CAD and CAM techniques furnishes some advantages, regarding 3D determination of the patient's jaw anatomy and fabrication of both anatomical models and surgical guides (Verstreken et al. 1996). In this paper we will present Rapid Prototype (RP) use as a tool, able to produce solid models of a maxilla in order to allow pre-surgical conditions evaluation in a patient who has lost bone tissue and needs dental implants. In this process, three-dimensional reconstruction has been made from a bi-dimensional image file, obtained by Computerized Tomography (CT) and a set of partial and total biomedical models have been manufactured to allow maxilla analysis. Rapid Prototyping technique used has been three-dimensional printing (TDP or 3DP) which allows a good reality simulation.

1 INTRODUCTION

In this study we will present Rapid Prototyping (RP) use as a tool to manufacture a biomedical 3D model from a human maxilla for pre-surgical study procedures.

The patient has suffered bone tissue loss and is intended to evaluate if it is possible and which are the best maxilla regions to promote bone tissue regeneration in order to obtain the needed thickness to apply the dental implants.

It is meant to do 3D reconstruction of a biomedical model from a 2D image file obtained from Computerized Tomography (CT) scan. After this reconstruction it is used Rapid Prototyping technology – Three Dimensional Printing (3DP or TDP) to produce the solid model.

By evaluating the conditions presented from the 3D model a previous surgery plan will be performed and presented to the patient to ensure that he is aware of his condition and the needed procedures that will lead to his treatment.

1.1 Maxilla bone tissue loss

With teeth loss the stimulation that allows alveolar bone to keep growing and maintaining, disappear, leaving place to a degenerative process that makes, in the beginning, bone edge stretching and trabeculae decrease and for last, global bone height shortening (Cardoso et al. 2002).

Posterior maxilla has a poor bone quantity and volume, reduced by pneumatization of maxillary sinus

(McCarthy et al. 2004). To oppose that anatomical limitation, maxillary sinus elevation has been one of the common surgical procedures in dental implants treatment (Mazor et al. 1999).

Requisites for the implant osseointegration success are the reconstruction material, implant design and surface finishing, surgical technique, reception place and charge conditions.

As example of used reconstruction material we can refer the allogene bone (like bovine bone), alloplastic materials (usually hydroxyapatite) and autogene bone that can be obtained from extrabuccal areas like iliac bone or cranial calota or from intrabuccal areas like the tuberosity and the mentonian and back molar area. However, autogene bone is the one that presents the nearest pattern from the ideal to buccal bone reconstruction (Graziani et al. 2004).

Maxillary sinus elevation procedure can be made in two steps with a cicatrization phase from about 4 to 6 months in order to allow biological integration of the added material (Schlegel et al. 2003). After this, implants are placed in position.

Depending of the reminiscent alveolar bone quantity, implants collocation can be made, simultaneously, at same time than bone addition for maxillary sinus elevation (Sendyk & Sendyk 2002) (Wragg et al. 2004), having as advantage in surgical phase the cicatrization period shortening, less surgeries and a lower risk of added bone re-absorption (Chiapasco & Ronchi 1994) (Misch 2000) once the implant, it self, acts like a support. However, this technique is only possible in cases where can be obtained a good

primary stability, usually in situations where there is, at least, 5mm of bone.

Used techniques for maxillary sinus elevation, usually, include a reception place enlargement using a wide variety of materials. The most used technique is the one that allows lateral access (windows), in which implants can be placed in areas considered inadequate by the insufficient bone anatomy (Avera et al. 1997). In cases where only some bone atrophy can be registered there are used osteotomes through an access in definitive place implants position, gradually expanding the bone and apically displacing it in the maxillary sinus to obtain a localized elevation between 2 and 7 mm (Toffler, 2004), being this one the less invasive technique.

1.2 CT images conversion to 3D models

In the conversion process of a computerized tomography in to a 3D model, it is needed a sequence of cross sections from the study object. Using 3D reconstruction software it is possible to transform these bi-dimensional images in a three-dimensional model that can be used to produce a solid model in rapid prototyping equipment (Foggiatto 2006).

Images obtained from computerized tomography obey to the international standards from DICOM (Digital Imaging and Communications in Medicine) pattern. Those are obtained from axial cuts of the study area and the equipment should be settled to the less possible thickness, once the lower this value is, better will be the model quality (Foggiatto 2006).

1.3 Rapid prototyping and some medical applications

Rapid Prototyping is the automated manufacture of physical objects. It is an additive-constructive process, layer by layer that allows complex form objects direct production from three-dimensional data and that is used to manufacture solid prototypes (Rocha & Alves 2000). The geometries needed can be obtained using some CAD software or through the conversion of data proceeding from 3D Scanners, Computerized Tomography or Magnetic Resonance devices. The first techniques to Rapid prototyping become available in the eighties and were used to produce models and prototypes parts (Alves & Braga 2001).

One of the main applications of Rapid Prototyping is the fast way that is allowed in verifying new concept projects, when those are in the earlier stages or even in advanced phases of conception. In all Rapid Prototyping processes is used a 3D CAD model that is translated into an STL (Stereolithography) format file, (Souza et al. 2003) where all the model surfaces are converted in a triangle mesh.

In Biomedical Engineering field, using Rapid Prototyping techniques it is possible to produce several types of anatomical models and implant replica with educational purposes or to better understand a specific patient pathology. The models, depending of available techniques, can be made of paper, wax, ceramic, plastic or metal (Antas & Lino 2008). These models can be produced without finishing or color or have these finish operations done later to improve visualization. With educational purpose it is possible to manufacture implant replica with much lower cost than the implant value.

A great interest can be found in anatomical models manufacture from patient tomographic images. These models allow students from biomedical field to have an easier view of a specific pathology and compare it with normal anatomical models. To better understand image techniques and anatomy, it is also possible to compare, simultaneously, the original image (TC or MRI) and 3D solid model.

Medical professionals have cooperated with other field professionals in a way to optimize pre-surgical pathology analysis, shorten surgical times, create personalized tools, turn easier the communication with patients and, simultaneously, to explore the capabilities that this technology offers in personalized prosthesis design (Antas & Lino 2008).

Several manufacturing processes are available today, as Fused Deposition Modeling (FDM), Stereolithography (SLA), Selective Laser Sintering (SLS), Tridimensional Printing (TDP or 3DP) and Laminated Object Manufacturing (LOM) among other specific processes.

2 METHODOLOGY

After patient's authorization for TC images be used, these were transferred to the computer where would be done image processing and removed all personal information data.

The process to obtain the anatomic model is composed by the following steps:

- Pre-processing from bi-dimensional images and reconstruction from the surface between the contours is done in image processing software ScanIP®. This step is done by using image processing operation such as threshold, *floodfill* and *paint*, which allow the creation and distinction of the masks, based in image grey levels. These masks can be defined through the color choice done by user allowing giving the desired contrast degree to the model for an easier visualization as well to enlighten the desired elements.

Figure 2. Images pre-processing done in ScanIP® software.




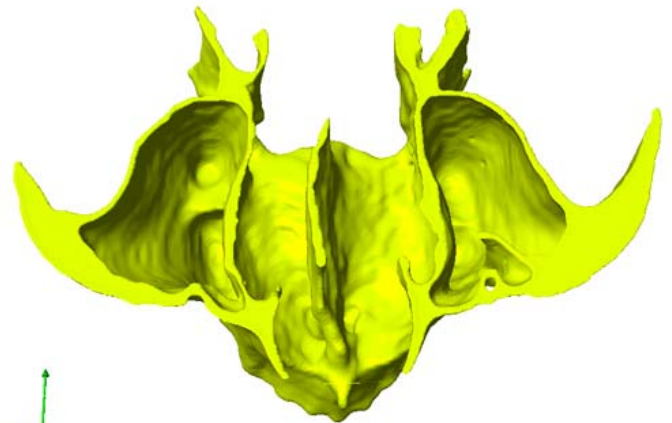
Figure 1. Image pre-processing done in ScanIP®.

First step of conversion consisted in 3D representation through the image processing application that allow closed volume visualization, after a segmentation operation based in the signal intensity – *thresholding*. This interactive application allow the user to detect and select contours in the maxilla area by doing a redefinition of grey levels that led to a separation of the bone from soft tissues. This operation applies gray levels recognition algorithms allowing, this way, a bigger grade of automatization.

After obtaining the contours with the desired quality, those are enhanced in a manual way using *paint* and *floodfill* operations. These operations consist in adjusting the obtained contours to the shape of the elements intended to represent and model. This step reveals it self as the most time consuming once the contours should be adjusted in more than one orientation (with axis changes) and in a manual way in each image to be processed.

- Rendering and 3D visualization that allow following work development during the previous step, to detect and correct possible imperfections. 3D rendering is done by the application of a consecutive planar triangle mesh from the masks defined in previous steps. Combining these two last phases it is possible to do an iterative process with the objective of present the model as close to the reality as possible.

In figure 1 it is possible to see model imperfection in a phase previous to manual masks adjustment.



ment.

Figure 3. Rendering and 3D previewing of maxilla total model in ScanIP® software.

In this case, not only a complete maxilla model have been produced, but also a global model divided in five transversal sections with the aim to allow a better view of the width of cortical bone along the maxilla.

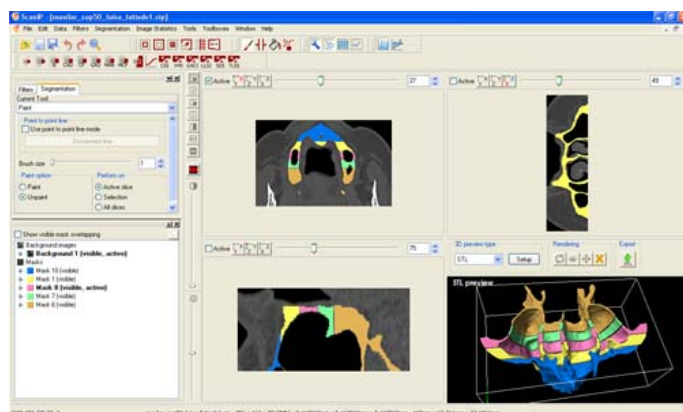
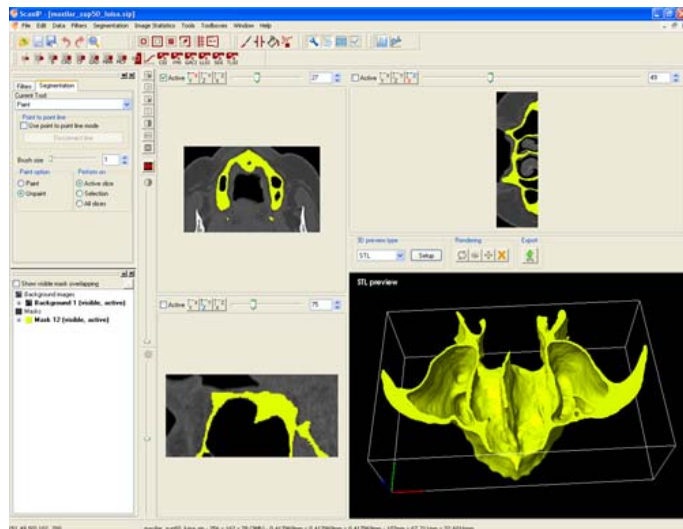
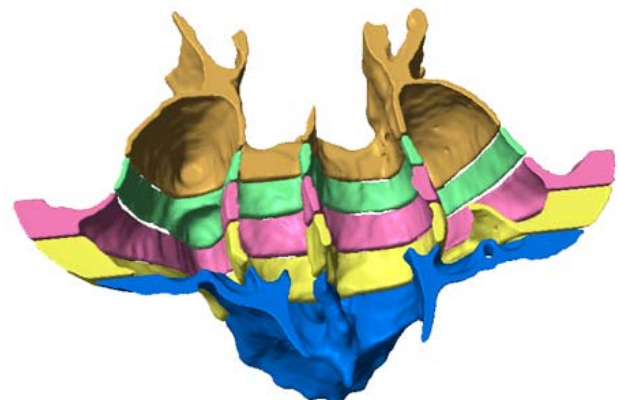


Figure 4. Rendering and 3D previewing of maxilla transversal sections in ScanIP® software.

- STL (Stereolithography) data generation allows combining all the active masks in a single file or the creation of several files with distinct masks.

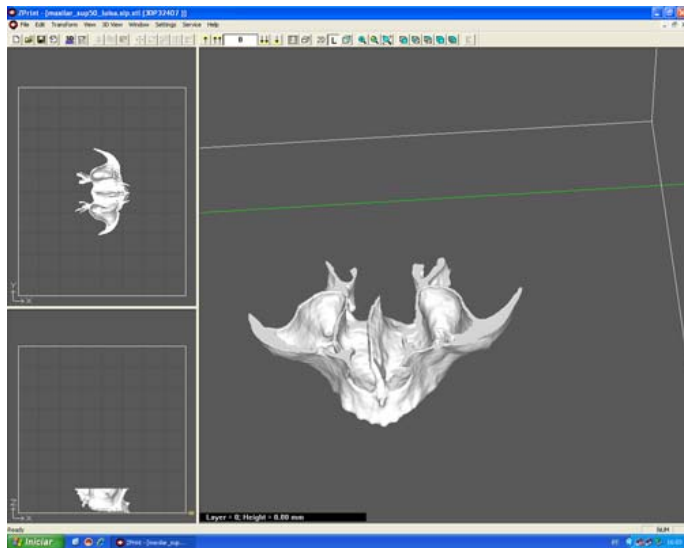


Figure 5. STL file visualization in printing software ZPrint®.

Contained data in this kind of files consist in the conversion and translation from the 3D model mesh outputted from image processing software in to a printing format recognized by the rapid prototyping device. This format contains the model layer division in a way to allow the layer by layer printing.

- Model manufacturing in Rapid Prototyping device Zprinter 310 from ZCorp.



Figure 6. Complete model manufacturing.

In the images from figure 6 it possible to visualize several phases from model manufacturing, going from the layer impression until the cleaning of the residual dust.

- Finishing that includes removing and recycling of excess material and model material consolidation.

Cleaning operations consist in the global remove, through compressed air action, of the non used dust to obtain an irregular but non dusty surface. After that, model surface consolidation is done by applying an epoxy resin or cyanoacrilate layer (Queijo & Rocha 2009).

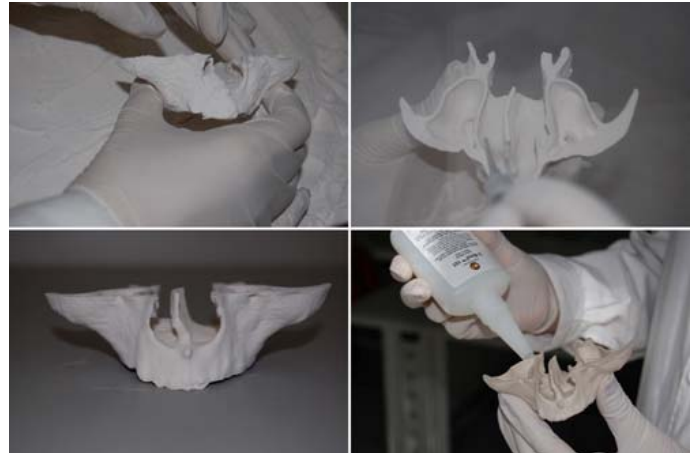

Figure 7. Cleaning, recycling and consolidation operations.

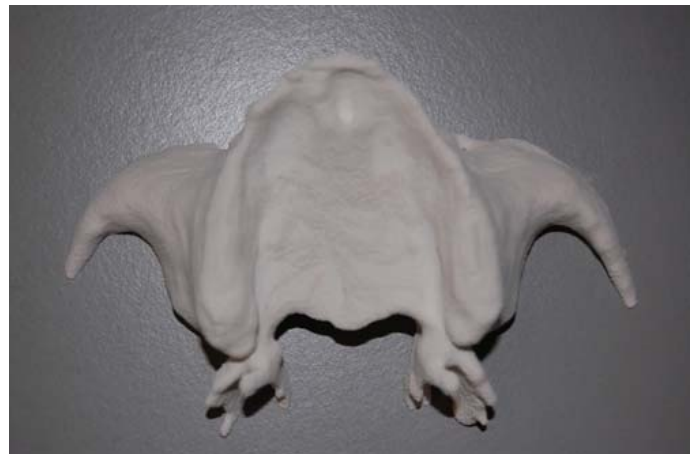

Figure 8. Manufactured and ready to use global 3D model.

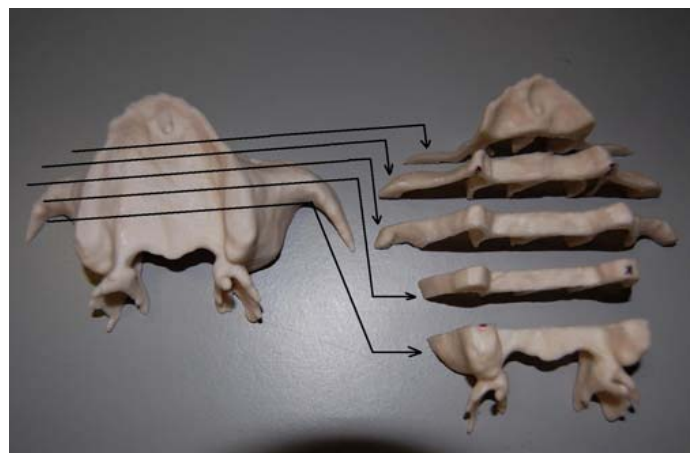


Figure 9. Global 3D model and corresponding transversal sections

3 CONCLUSIONS

3D replicas sections or global models are useful in diagnosing, planning and surgery simulation. The visualization and the possible manipulation, by patients, from 3D replica allow them to understand their pathologies nature, surgical proceedings that should be done by surgeon as well to reduce anxiety face to the surgery need. By other side it is possible to the surgeon to plan all the surgery procedures considering the chosen techniques and material that are dependant from the analyzed problem.

With multidisciplinary teams cooperation it is possible to build, in a short period of time, 3D models that fulfill all the requirements to this applications.

In this case, by analyzing the global model and the five transversal sections – Figures 8 and 9, it is possible to, with a better accuracy, determine where the implants should be placed, considering the width of cortical bone available or, alternatively, determine where bone regeneration should be fomented to obtain a considerable cortical bone thickness that allows implants placement.

From that evaluation it became clear that the most suitable areas for implants placement would be the ones marked in the model and that can be seen in Figure 10.

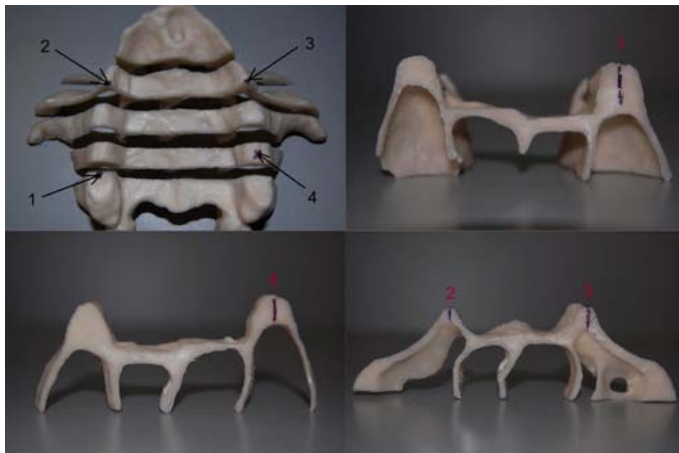


Figure 10. Preferred locations for bone regeneration and implants placement.

Clinically and after evaluation of the bone condition in the 3D sections replica from the patient maxilla it has been decided to place 4 implants, trying to turn possible an acrylic prosthesis retention through attachments.

Implants will be placed in canine teeth area – two of them, while the other two will be placed in the second molar area, as can be observed in the figure. Due to the several patient bone tissues loss it should be used the techniques referred previously.

This way, in the posterior implants (Fig. 10 - number 1 and 4) it will be used two Zimmer Tapered

Screw-Vent[®] implants with 4,7 mm diameter and 11 mm long, by applying an osteotome bone condensation technique. Once the total height needed is about 5 mm the needed bone tissue will be gained by using osteotomes and applying Gen-oss[®] - Osteobiol[®] allogene bone.

In the anterior implants it will be performed a 2 steps surgery procedure. In first phase it will be opened a gingival side “window”. With proper instrumentation is slided the mucous membrane through which is applied Gen-oss[®] - Osteobiol[®] to perform bone regeneration. To close the open wound, a collagen membrane is applied to improve cicatrization and then, gingiva is sutured.

This last step will need a 6 months period of consolidation after which is needed a new evaluation to find out if the osseointegration was well performed and if no problems have arise since then.

In case of positive behavior confirmation it will be processed the surgery to apply the dental implants.

By showing these models to the patient he could understand the nature of his problems and have all the elements that allow him to choose if surgery should be considered or not. By not being an easy case, patient should always have the ability of choose if they want to proceed with the treatment and be aware of the risks involved.

Surgeon, become able to start planning surgery by estimating the work to be done and by doing one first evaluation to the place where he should intervene through this 3D replica.

In this line, and applied to the same subject, further work will consist in 3D modeling of medical devices (implants) and those will be inserted in the definitive positions assigned by medical staff allowing, this way, a more detailed surgical planning with insertion points and angulations well determined aswell with the definitive quantity of bone to be regenerated.

Another model will, then, be prototyped with all the areas aimed for intervention highlighted to better establish the definitive procedure.

REFERENCES

- Alves, L. & Braga, F. 2001. Protoclick, prototipagem rápida. Porto. Protoclick, INEGI.
- Alves L. & Rocha J. 2000. Desenvolvimento de moldações cerâmicas compósitas para o fabrico de ferramentas metálicas. O Molde.
- Antas, A. F. et al. 2008. Utilização das Tecnologias de Prototipagem Rápida na Área Médica. 5º Congresso Luso-Moçambicano de Engenharia. Maputo. Moçambique.
- Avera, S. P. et al. 1997. Histologic and clinical observations of resorbable and nonresorbable barrier membranes used in maxillary sinus graft containment. International Journal of Oral and Maxillofacia. Implants. V. 12, n. 1, p. 88-94.

- Cardoso, R. F. et al. 2002. Levantamento de seio maxilar - Odontologia. Periodontia, cirurgia para implantes, cirurgia, anestesiologia. São Paulo: Artes Médicas, p. 467-81.
- Chiapasco, M. & Ronchi, P. 1994. Sinus lift and endosseous implants-preliminary surgical and prosthetic results. *European Journal of Prosthodontic Restauration Dent.* v. 3, n. 1, p. 15-20.
- Foggiatto, J. A. 2006. O Uso da Prototipagem Rápida na Área Médico-Odontológica. *Tecnologia & Humanismo.* v1, p. 60-68. Curitiba. Brasil.
- Graziani, F. et al. 2004. G. Comparison of implant survival following sinus floor augmentation procedures with implants placed in pristine posterior maxillary bone: a systematic review. *Clin. Oral Impl. Res.* v.15, p. 677-682. Inglaterra
- Hallman, M. and Nordin, T. 2004. Sinus floor augmentation with bovine hydroxyapatite mixed with fibrin glue and later placement of nonsubmerged implants: A retrospective study in 50 patients. *Int. J. oral Maxillofac. Implants,* v. 19, n. 2, p. 222-7.
- Maló, P. et al. 2008. A new approach to rehabilitate the severely atrophic maxilla using extramaxillary anchored implants in immediate function: A pilot study. *The Journal of Prosthetic Dentistry* 100(5): 354-366.
- Mazor, Z. et al. 1999. Sinus augmentation for single-tooth replacement in the posterior maxilla: a 3-year follow-up clinical report. *Int. J. oral Maxillofac. Implants,* v. 14, n. 1, p. 55-60.
- Misch, C. E. 2000. Cirurgia para levantamento do seio maxilar e enxerto sinusal. In: Misch, C. E. *Implantes dentários contemporâneos.* 2ª ed. São Paulo: Ed. Santos, p. 469-95.
- McCarthy, C. et al. 2003. Sinus augmentation bone grafts for the provision of dental implants: Report of clinical outcome. *Int. J. oral Maxillofac. Implants,* v. 18, n. 3, p. 377-82.
- Netto, A. C. S. et al. 2003. Prototipagem rápida: uma ferramenta de projeto para a redução do tempo de desenvolvimento e melhoria de qualidade de produtos. IV Congresso Brasileiro Gestão e Desenvolvimento de Produtos. Gramado RS. Brasil.
- Queijo, L. et al. 2008. A prototipagem rápida na modelação de patogenias. 3.º Congresso Nacional de Biomecânica. Bragança. Portugal.
- Rocha, J. 2000. Moldações Cerâmicas Compósitas. FEUP. Porto. Portugal
- Rocha, J. & Alves, L. 2000. Utilização de moldações cerâmicas compósitas no fabrico de ferramentas metálicas. 2º Encontro nacional do colégio de engenharia mecânica da ordem dos engenheiros. Coimbra. Portugal.
- Schlegel, K. A. et al. 2003. Histologic findings in sinus augmentation with autogenous bone chips versus a bovine bone substitute. *Int. J. oral Maxillofac. Implants,* v. 18, n. 1, p. 53-8.
- SENDYK, W. R. & SENDYK, C. L. 2002. Reconstrução óssea por meio do levantamento do assoalho do seio maxilar. In: Gomes, L. A. *Implantes osseointegrados – Técnica e Arte.* São Paulo: Ed. Santos, Cap. 7, p. 109-22.
- Souza, M. A. et al. 2003. Integrando reconstrução 3D de imagens tomográficas e rototipagem rápida para a fabricação de modelos médicos. *Revista Brasileira de Engenharia Biomédica,* 19(2) p. 103-105.
- Toffler, M. 2004. Osteotome-mediated sinus floor elevation: a clinical report. *Int. J. oral Maxillofac. Implants,* v. 19, n. 2, p. 266-73.
- Verstreken K. et al. 1996. Computer-assisted planning of oral implant surgery: A 3-dimensional approach. *International Journal of Oral and Maxillofacial Implants* 11:806.
- Wang, P. D. et al. 2002. One-stage maxillary sinus elevation using a bone core containing a preosseointegrated implant from the mandibular symphysis. *Int. J. Periodontics Restorative Dent.* v. 22, n. 5, p. 435-9.