

Diagnostic Evaluation of Chronic Venous Insufficiency Cases Using Thermal Imaging

Marta C. F. Martins¹, Luís M. F. Ribeiro¹, Jorge Cury²

1. Polytechnic Institute of Bragança, Bragança, Portugal

2. Department of Surgery, ULS Bragança Hospital, Bragança, Portugal

SUMMARY

The use of infrared thermography in surgery of Varicose Veins on the inferior limbs is presented. The study was executed at Polytechnic Institute of Bragança and at the Regional Hospital of Bragança, Portugal. The most suitable steps to measure with this technology were determined prior to the clinical studies, where a minimum waiting time of 10 minutes was determined for each individual to reach thermal equilibrium. Both inferior limbs were compared for each patient and it was found that in 75% of the cases there was an aggravation of the healthier leg. In one of the cases residual veins appear. It was concluded that regular thermographic exams on post-operative allow a closer follow up of the recovery of the operated limb, as well as the evolution of the non-operated limb.

1. INTRODUCTION

This study show the early exploration phase for Varicose Veins cases recommended for safenectomy at the Surgery Department of the ULS Bragança Hospital, Portugal. This work involved preliminary tests to develop an appropriate experimental protocol to study the inferior limbs, and analyze clinical cases with the support of the Surgery Department at the Bragança Hospital, Portugal.

One of the most common manifestations of venous insufficiency, or venous reflux are Varicose Veins. They are the source of aching pain and discomfort and may require medically necessary treatment, being the most extreme the surgical option the removal, or closing off, the affected vein. Surgical option accounts for the severity of the symptoms, the type of vein and the source of venous reflux. Clinical examination is also supported by blood exams, Eco-Doppler soundings or other imaging studies in order to accurately assess all of the sites of venous reflux.

Blood flow can be assessed by many methods including the washout technique, laser Doppler flowmetry, and medical infrared thermal imaging. Of those, infrared thermography has the advantages of being noninvasive, fast, reliable, contactless, and capable of producing multiple recordings at short time intervals. It is also absolutely safe for patients and medical staff (1, 3).

The aim of this work is the exploratory use of infrared thermography within venous insufficiency cases. Thermography visualization was made at the inferior limbs where cases of varicose veins were monitored over time with a camera FLIR® T365 model.

The most adequate steps to measure with this technology were determined prior to the clinical studies. A team of engineers and medical doctors evaluated the thermographic images for a better analysis and interpretation of the results.

With this work, it was found that the thermography was a very useful technique in this particular pathology, being easy to handle and reliable in diagnosis. From this technique we were able to verify whether the surgery had been successful or not, and identify varicose veins that had not been identified earlier with standard Eco-Doppler exam.

1.1 Varicose Veins

The normal way the saphenous vein works is by allowing blood to flow from the lower leg to the heart (a simple pipe or conduit use). Venous valves stop the backward flow of blood once it is pushed forward by muscles or gravity. Unfortunately, valves can become damaged allowing backward flow, creating pools in the lower leg and causing swelling as well as other problems. The term used by physicians for this abnormal state is chronic venous insufficiency (CVI). Another sign that there is abnormal back-ward blood flow in the lower leg is the presence of varicose veins, in which they are

often seen as dilated vein branches coming off the saphenous vein and easily seen beneath the skin (2).

1.2 Saphenectomy or Saphenous Venous Stripping

Standard open varicose vein surgery has been used to treat uncomplicated varicose veins for over 100 years. The specific techniques of the operation have been subject to regular, and often cyclical, change over the years. However, the essential aim of the operation, to ligate and disconnect the great (GSV) or small saphenous vein (SSV) at its junction with the deep venous system has remained constant (4). The traditional surgical treatment for venous insufficiency of the saphenous vein involves two primary goals. The first is to eliminate backward blood flow (reflux) in the saphenous vein and its tributaries. The second is to remove unsightly and protruding varicose veins through tiny incisions (phlebectomy). Improvement to the method over the years has allowed most procedures to be done on an outpatient basis.

Saphenous vein stripping involves making a small incision at the level of the groin to expose the beginning of the saphenous vein and its branches, and a separate incision at or near the level of the knee. A wire stripper is then inserted into the vein and the vein is disconnected at these two incisions. The vein is attached to the wire stripper and is pulled (ripped) from where it lies. Thus the term “stripping” of the vein was what it came to be called. Small separate skin cuts (incisions) over the areas of abnormal vein dilation are made along the thigh or calf for removal of branch varicose veins that were not attached to the main trunk of the saphenous vein or where not removed at the time of stripping.

Compression bandaging is used from the ankle to the level of the thigh for several days to reduce the amount of bruising and discomfort from the procedure. The patient is allowed to walk to comfort levels immediately after surgery with instructions for leg elevation when discomfort develops and when retiring to bed. This procedure can be often based using local anesthesia but more normally has been performed in an ambulatory setting with either a general or spinal anesthetic (2).

2. METHODS

A particular protocol for a FLIR®, model T365, camera (Fig. 1) was developed for this pathology. This protocol differs from Bagavathiappan et al. (1)

because functional tests were also included to enhance physical limitations provoked by the disease and are better captured by thermography.



Fig. 1 - Camera FLIR®, T365 model.

The determination of the experimental protocols results on the adaptation of the existing protocols, which consist in a set of steps and cares such as caution on the application of lotions, avoiding excessive sun exposure, shaving or exercise. Those are some of the examples to be avoided before a thermographic exam.

The subjects were placed at rest for a period of 10 minutes in a controlled temperature room in order to conclude acclimatization process.

A black background was also used to avoid temperature contamination of the surroundings and the capture of images was made from multiple angles. It was considered an emissivity of 0.98, the relative humidity (50%) and the distance from camera to the object (0.50 m).

2.1 Distance and angle from the camera to the object

The infrared thermal camera was positioned 0.50 m away from the limb and the images were taken in three views: anterior, posterior and lateral. As the images are from a curved surface (limb) several images – parallel to the surface - are necessary to fully capture the emitted radiation.

2.2 Exploratory Tests and Methodology

The exploratory tests were made in four healthy subjects, of approximately 20 years old, providing a reference for neutral situation. The tests were performed in a horizontal position, where the leg was at rest, and then vertically.

Initial measurements of lower extremities of the healthy patients showed normal skin surface temperature. The thermography protocol followed was:

1. Turn on the camera and leave it to calibrate for 5 - 7 minutes;
2. Leave the subject rest with the lower limbs to acclimate (remove all the clothes of this area) in a room for 10 minutes;
3. Put the black background behind de limb;
4. Leave the camera 0.50 m to the subject;
5. Collect images from multiple angles.

The results presented of the healthy subjects are only of the right leg since does not distinguish differences between the two relevant.

3. RESULTS AND DISCUSSION

The preliminary tests were able to provide a reference for neutral situation. In Fig. 2 there are four healthy subjects. It is observed uniform temperature variations along the surface.

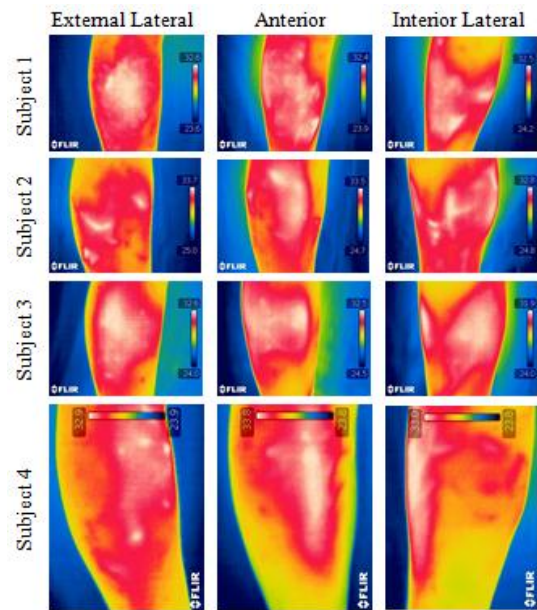


Fig. 2 - Right inferior limb of the healthy subjects in the anterior and lateral views.

Four clinical cases are presented: one male and three females, with Varicose Veins pathology identified in only one leg – with surgical recommendation. Exams in both legs with standard procedure produced the same information for the leg with the pathology. However, thermography clearly unveiled – or highlighted – additional Varicose Veins in the considered healthy legs, not identified by clinical examination or by imaging methods commonly used in clinical practice. This

early identification of venous pathology demonstrates the advantages of the Thermal Imaging as a quickly, inexpensive and noninvasive diagnostic tool, and could lead to other course of treatments avoiding radical solutions such as Saphenectomy.

3.1 Clinical Case 1

The patient was a 61-year-old female with recur-rent varicose veins. This patient had undergone a saphenectomy. A possible duplication of the saphenous vein complicated the venous system of the right leg leading the patient to a second surgery. Images were collected with the patient laid and standing up. When the patient was at rest one do not observe the same temperatures as standing (fig. 3). While lying, the blood flow is smaller, being that one of the characteristics of the varicose veins. Then, when the patient stands upright position, blood flow increases because there are no competent valves that can control the flow.

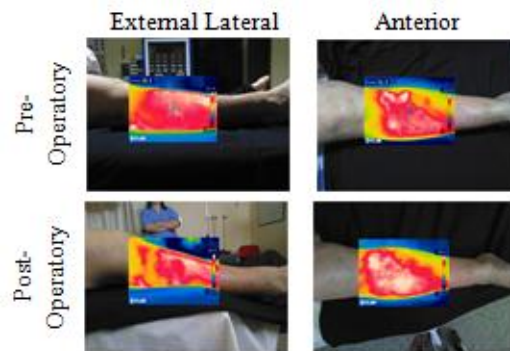


Fig. 3 - Inferior right limb before and after surgery at rest.

In this case it was not possible to identify pathology when the patient was at rest. However, the results confirmed the venous pathology and the recur-rent varicose veins when the patient was standing. It was possible identify with the thermographic exam the same findings the Eco-Doppler exam. In the post-operatory images (Fig. 4) it is possible to observe residual veins that are a common complication of the surgical treatment. An alternative hypothesis refers to the ill marking of the veins in pre-operatory exam. Thus an intra-operatory exam would be a way to ensure the success of the surgery when the marking is not completed. The images of the post-operation were collected 39 days after the surgery.

In this case there was an aggravation of the healthy leg (Fig. 5) that may be due to overload in the leg while the operated leg recovers from the surgery.

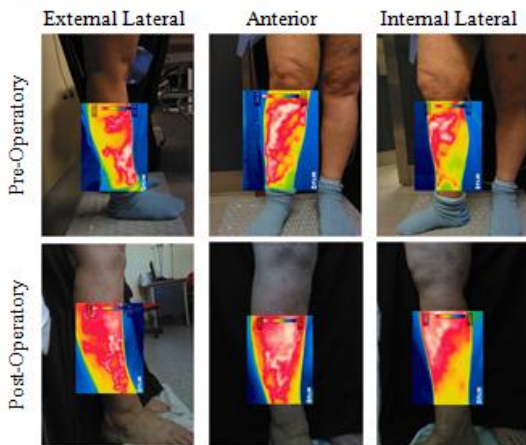


Fig. 4 - Affected limb (right leg) of the clinical case 1 before and after surgery.

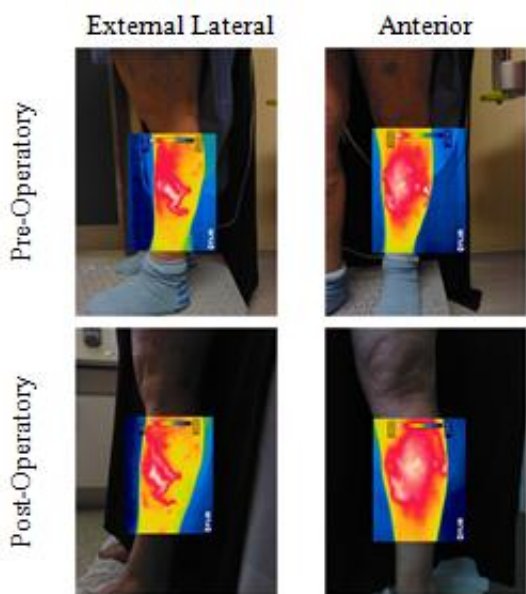


Fig. 5 - Right inferior limb not indicated for surgery. Identification of pathology in the external lateral face of the limb.

The images of the pre and post-operative were not taken always at the same distance and angles but approximate values of the vein dimension were determined by simple triangulation. One of the varicose veins of the healthy leg (Fig. 6) increased of $232\% \pm 5\%$.

3.2 Clinical Case 2

An 18 year-old male with a visible dilatation of the vein of the inferior left limb. The images were collected in pre-ambulatory environment, and in this case it was possible to identify abnormal temperature areas even when the patient was at rest (Fig. 7).




Fig. 6 - Left leg. Varicose veins compared before and after the surgery to the right leg.

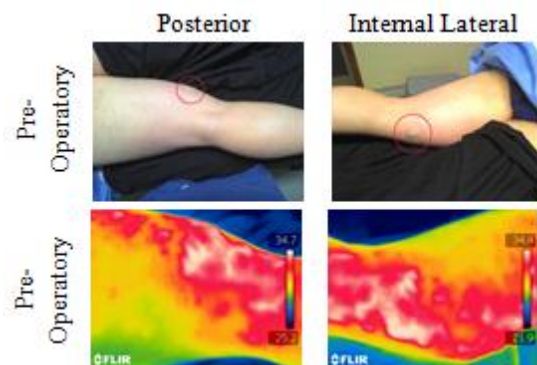


Fig. 7 - Affected limb (left leg) of the clinical case 2 before surgery (Original and thermal images).

When the patient was standing the pathology was better visualized because of the increase of the blood flow (as previous mentioned in 3.1). The affected area was only in the internal part of the leg, so the results presented are only of the area that presented this pathology. The images of the post-operation were collected 39 days after the surgery. Although not being common in younger people, this pathology may be presented in people with genetic predisposition or with high intensity of sport activity, our case.

The pathology is evident and consistent with the Eco-Doppler. The saphenectomy intended to solve the main trunk of the saphenous vein. From a medical point of view the surgery was successful (Fig. 8). It was also possible to identify varicose veins in the healthy leg (Fig. 9) where the Eco-Doppler had not identified any abnormality. In this case the increase of the varicosity of the healthy leg (Fig. 9) was 4.3% within our margin of error. In this case we cannot conclude that there was an increase of the varicose vein in the healthy leg.

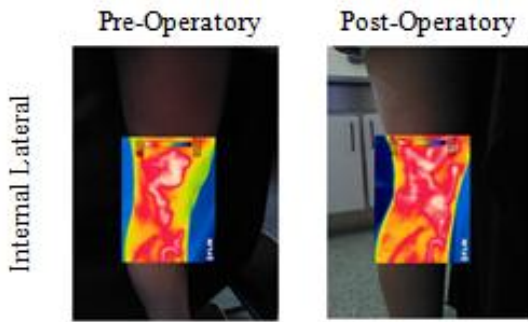


Fig. 8 - Left inferior limb before and after surgery only in the lateral view.

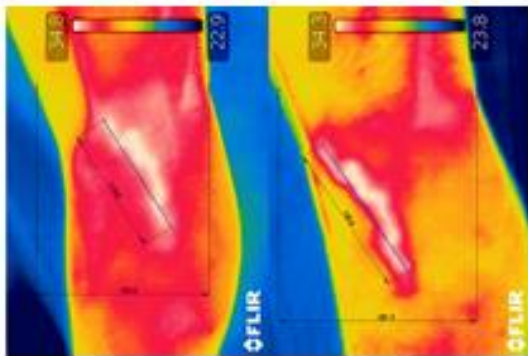


Fig. 9 - Right leg. Varicose vein compared before and after the surgery to the left leg.

3.3 Clinical Case 3

The third clinical case was of a 60-year-old female indicated for a saphenectomy in the left inferior limb. The most evident vein was located in the posterior face of the limb. In Fig. 10 it is visible the vein with the thermographic exam confirming the pathology. The images of the post-operation were collected 18 days after the surgery, and it is well perceptible the improvement of the area presenting a more uniform temperature of the intervene area. There is an improvement on the posterior face of the limb. At the post-operative consult the patient claimed to feel well and free of pain.

3.4 Clinical Case 4

A 62 year-old female with indication of surgery to the right inferior limb. In this case it was possible to see through the thermal images the pathology very clearly even when the patient was lying (Fig. 11). Then, the venous pressure is more passive, as the pressure of the blood is lower in the veins to venous return.

The post-operative images were collect 17 days after the surgery.

Undoubtly, the best position to visualized and diagnose varicose veins is when the patient is standing (Fig. 12). This is another case in which there was a significant improvement in the leg after surgery, observing in the post-operative a uniform surface temperature. Given that these images were collected 17 days after surgery, we can also speak on the expertise of the surgeon.

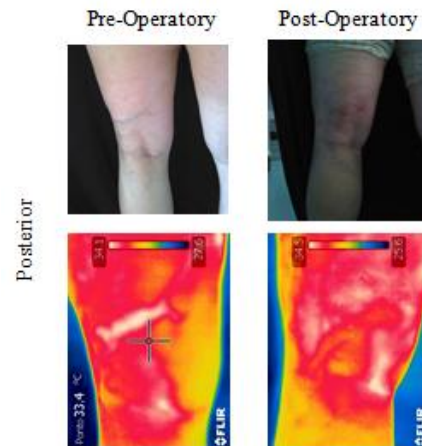


Fig. 10 - Left inferior limb before and after surgery.

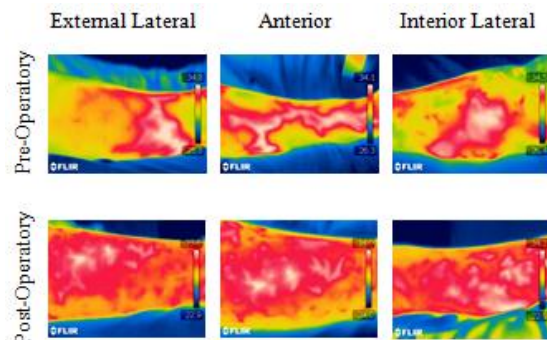


Fig. 11 - Right inferior limb before and after surgery.

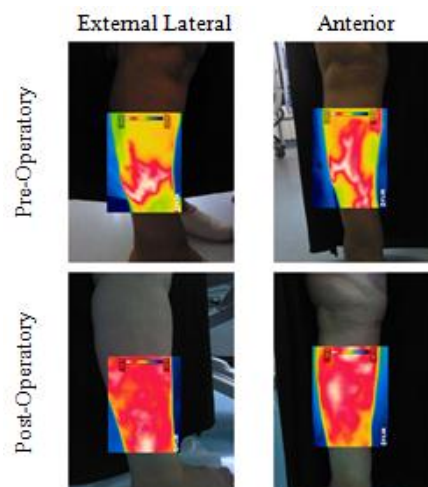


Fig. 12 - Right inferior limb indicated for surgery (pre and post-operative).

In this case was also possible to identify pathology in the healthy leg (Fig. 13). However the angle of capture of the images in the pre-operative wasn't exactly the same than the post-operative therefore is not possible to conclude if there is an evolution of the varicose vein.

3.5 Marking of varicose veins

In some clinical cases, the opportunity arose to collect images while the surgeon was marking the varicose veins with a marker. In Fig. 14 we observe a surgeon tagging the leg with a marker. In this case the surgeon was guided by Eco-Doppler information and touch (by palpation of the leg). We observe that the markings are consistent with the warmer spots on the leg.

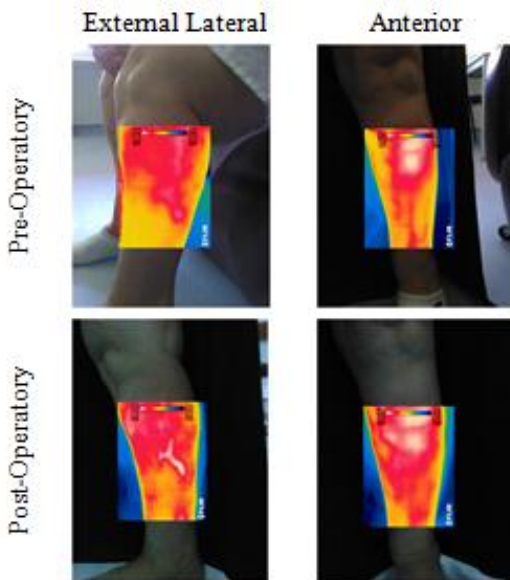


Fig. 13 - Left inferior limb not indicated for surgery, before and after the operation of the right leg.

The marking is done with the patient standing, but it can be considered doing with the patient lying with thermography as a diagnostic support. In the point of view of a surgeon, in the case 1 there were some varicosities spots to mark. In the future to help avoid these types of flaws, thermography can be a very useful technique in the support of the pre-operative exam. It would be also a great support technique as a intra-operative exam (Figs 15-16), helping the surgeon to evaluate the result of the surgery.

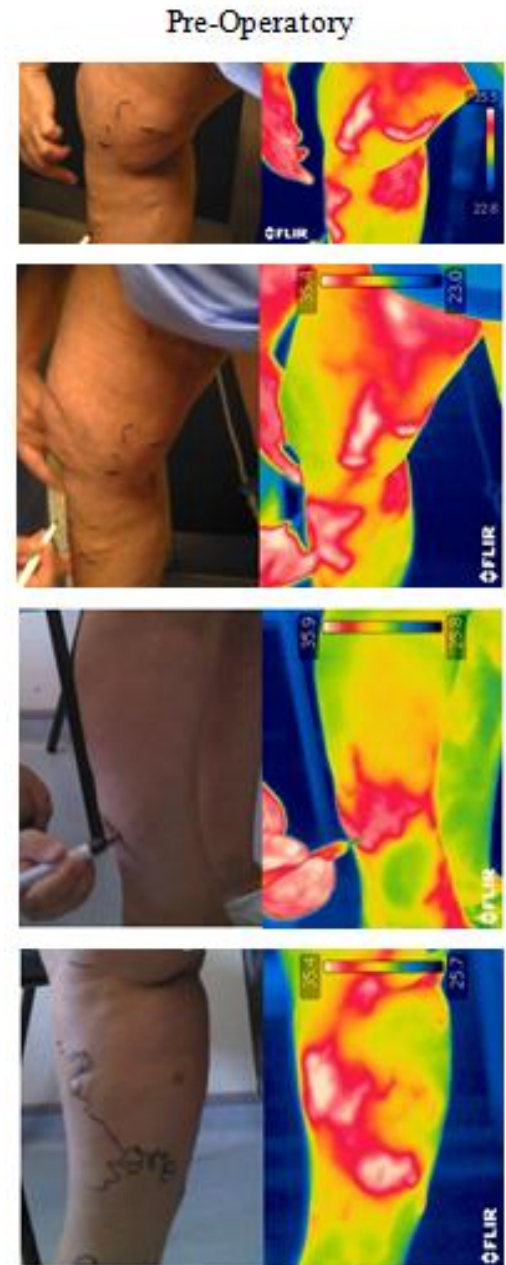

Fig. 14 - Marking of the varicose veins in the pre-operative exam.

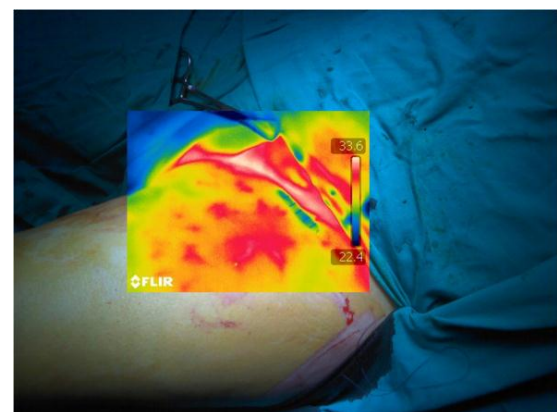


Fig. 15 - Intra-Operatory thermography exam.

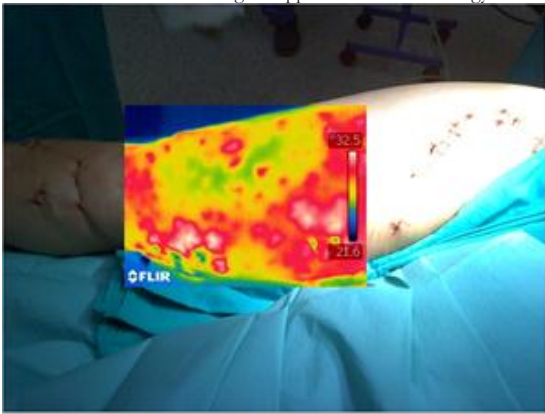


Fig. 16 - Intra-Operatory thermography exam of a saphenectomy surgery.

3.6 Discussion

Analyzing all the images collected on the lower limbs of healthy subjects and clinical cases came to the conclusion that the collection of data when the patient is at rest may also be relevant. In healthy subjects was not perceptible because did not exist pathology. However, in clinical cases it was found that it was possible to observe varicose veins at rest. Factors such as distance, angle, capturing light, or other factors that weren't determined for lack of time, may be involved in data collection. It was found that in a standing position the pathology is better visualized: the blood flow increases, and the pressure in the veins, due to poor venous return, is more evident.

Except for case three, it was noted the worsening of varicose veins identified in the healthy limb.

The success of the surgery depends primarily on factors as:

1. The expertise of those who operate;
2. The duration of the surgery;
3. The ability to visually evaluate.

The recovery of the surgery depends mainly of three factors:

1. The illness (the severity of the pathology, such as case 1 in which there are complications to the appearance of residual vein, or the existence of genetic predisposition, as in case 2);
2. The patient (the care that the patient have after surgery for a good recovery, i.e., an active life, not sedentary, avoid excessive sun exposure, avoid sitting or standing positions for long periods of time, good diet, etc.);
3. The expertise of the surgeon (ability to evaluate and verify the results in the intra-operative, the

expertise of those who operate, the visual diagnosis of who marks the pathology, etc.).

4. CONCLUSIONS

In this work it was proposed exploratory testing using thermography. For this it was learned to master the technique, the handling of the camera, as well as processing and interpretation of results, thus achieving a suitable experimental protocol.

It was concluded that the ideal position for the collection of data was standing even for healthy patients as the ill patients. In clinical cases it was more evident that the best position to collect images was standing because of the pressure exerted in the veins.

Other factors such as distance to the object and the camera's shooting mode were defined. Angles to capture images were defined and the use of black surfaces for better image capture. The use of the black background allowed to mitigate contamination from other sources, such as reflection light.

The creation of thermography protocol was effective in collecting data, and the result of the captured images and the diagnosis using this technique - satisfactory. The technique proved to be reliable for the diagnosis of the pathology being possible to assess the success of the surgery. Through this it was possible to identify varicose veins that were not previously detected in the Eco-Doppler exam.

Through thermography it was observed the worsening of varicose veins that were not identified in the healthy limb. This increase may have been caused by overloading while the operated leg recovered from surgery. It was also noted that this technique could be very effective in marking varicose veins since the difficulty of visually evaluate can influence the marking, and thus compromise the success of the surgery.

In addition to the factors that may compromise the surgery it is also considered the disease. The patient may have a genetic predisposition for the disease. Recovery from surgery depends on the disease, the patient and the care that this have after the surgery (and once again the expertise of those who operate).

REFERENCES

1. Bagavathiappan S, Saravanan T, Philip J, Jayakumar T, Raj B, Karunanithi R, Panicker T, Korath MP, Jagadeesan K. Infrared thermal imaging

- EAT2012 Book of Proceedings – Appendix 1 of Thermology international 22/3 (2012)
for detection of peripheral vascular disorders. J Med
Phys 2009; 34, 43-47
2. Gloviczki P, Dalsing MC, Eklof BG, Moneta GL, Wakefield TW. HandBook of Venous Disorders. Hooder Arnold, 3rd edition 2009.
 3. Jones HRN. Radiation Heat Transfer. Oxford University Press, 1st edition 2000.
 4. Perkins JMT. Standard varicose vein surgery; Phlebology 2009; 24(Suppl 1), 34-41.

For correspondence:

Marta Martins, Luis Ribeiro
Polytechnic Institute of Bragança
Campus de Santa Apolónia
5300-253Bragança
Portugal
a19294@alunos.ipb.pt, frolen@ipb.pt

Jorge Cury
Department of Surgery
ULS Bragança Hospital
Av. Abade Baçal
5301-852 Bragança
Portugal
drjorgecury@hotmail.com

